



## Rhinoplasty without nasal packing and splinting

### Rinoplastika bez tamponade nosa i bez udlage

Dejan Vulović\*†, Jevta Kozarski‡§, Uroš Radivojčević\*†, Nenad Stepić‡§, Saša Milićević‡§, Nenad T. Petrović†||

Clinical Center “Kragujevac”, \*Center for Plastic Surgery, †Clinic for Ophtalmology, Kragujevac, Serbia; University of Kragujevac, ‡Faculty of Medical Sciences, Kragujevac, Serbia; Military Medical Academy, ‡Clinic for Plastic Surgery and Burns, Belgrade, Serbia; University of Defence, §Faculty of Medicine of the Military Medical Academy, Belgrade, Serbia

#### Abstract

**Background/Aim.** Most surgeons, at the end of corrective rhinoplasty, use endonasal tamponade and external splinting, primarily because of hemostasis and immobilization. Possible complications of this surgery are various. Pain, nose edema, palpebral swelling and ecchymosis, are the most common and usual. The aim of our study was to evaluate the incidence of nonaesthetic complications and the efficiency of corrective rhinoplasty without the use of tamponade and external splint. **Methods.** One hundred and fifty-one patients, who underwent primary corrective rhinoplasty without endonasal tamponade and without an external splint, were analyzed at the Clinical Centre “Kragujevac” in Kragujevac, Serbia, in the period 1999–May 2016. The surgeries were done by the same surgeon. Instead of a splint, sterile skin adhesive tapes were used. Study was prospective, consecutive case-series type. We analyzed the possible complications and subjective estimates of the patients who underwent primary corrective rhinoplasty in described fashion. In assessing postoperative pain, the visual analogue scale (VAS) in a range of 1 to 5 was used. Palpebral swelling and ecchymosis, were estimated 24h after surgery, by the Surgeon Periorbital Rating of Edema and Ecchymosis (SPREE) scale ranging from 0 to 5. The degree of restriction of nasal respiration was evaluated by the scale 1–4. The overall comfort of patients in the postoperative period was evaluated according to a scale: good, no opinion, bad.

#### Apstrakt

**Uvod/Cilj.** Većina hirurga, na kraju korektivne rinoplastike, koristi endonazalnu tamponadu i spoljašnju udlagu prvenstveno radi hemostaze i imobilizacije. Moguće komplikacije ove operacije su različite i najčešće su bol, otok nosa, i otok sa krvnim podlivima očnih kapaka. Cilj naše studije bio je da se proceni učestalost neestetskih komplikacija i efikasnost korektivne rinoplastike bez tamponade i spoljašnje udlage. **Metode.** Sprovedena je analiza sto pedeset i jednog bolesnika u Kliničkom centru “Kragujevac” u Kragujevcu, Srbija, u periodu od 1999. godine do maja 2016. godine, koje je operisao isti hirurg i uradio primarnu

The patient satisfaction with the aesthetic result was analyzed on 7th and 30th day after surgery, by a scale from 1 (very satisfied) to 5 (very dissatisfied). **Results.** There were 151 patients aged between 18–47 years. Females were more frequent (72.18%). Most of the patients (40.39%) had moderate pain. None of the patients had neither severe nor the worst pain and 59 patients had no pain at all. Eyelid edema and periorbital ecchymosis were moderate in all patients (100%). The other complications did not occur, apart from one (0.66%) unilateral epistaxis, on postoperative day 10. Most of the patients (52.97%), immediately after surgery, could freely breathe through the nose. The general impression of the patient comfort after surgery was mainly good (74.17%). The majority of patients (52.28%), were satisfied with aesthetic result after 7 days, and 52.32% after 1 month. There were very satisfied patients: on day 7 - 27.15% and on day 30 - 39.73%. **Conclusion.** We concluded that the rhinoplasty without using tamponade and immobilization was safe, comfortable and economical. The degree of pain, edema and ecchymosis were low, as well as the incidence of other complications.

**Key words:** rhinoplasty; surgical procedures, operative; postoperative period; postoperative complications; patient satisfaction.

korektivnu rinoplastiku bez endonazalne tamponade i bez spoljašnje udlage. Umesto splinta, korišćene su adhezivne sterilne kožne trake. Prospektivnom studijom, tipa uzastopne serije slučajeva, analizirali smo moguće komplikacije i subjektivne procene bolesnika kod kojih je urađena primarna korektivna rinoplastika na opisani način. Za procenu postoperativnog bola korišćena je vizuelna analogna skala (VAS). Dobijeni rezultati rangirani su od 1 do 5. Za procenu otoka i krvnih podliva očnih kapaka 24 sata posle operacije, primenjena je skala hirurškog periorbitalnog rejtinga otoka i ekhimoza (SPREE). Rezultati su rangirani od 0 do 5. Stepenski restrikcije disanja kroz nos evaluiran je u skali od 1 do 4. Opšti komfor u postoperativnom periodu operisani su oce-

nili kao: dobar, neodređen, loš. Zadovoljstvo bolesnika estetskim rezultatom je analizirano sedmog i tridesetog dana od operacije, na skali od 1 (veoma zadovoljan) do 5 (veoma nezadovoljan). **Rezultati.** Analiziran je sto pedeset i jedan bolesnik, starosti od 18 do 47 godina, a najviše je bilo mlađih bolesnika (prosečno 23,19 godina). Zastupljenost ženskog pola (72,18%) je bila veća, Umeren bol imalo je 47,02% bolesnika. Nijedan od njih nije imao jake ili najteže moguće bolove, a 32,45% bolesnika nije uopšte imalo bolove. Otok očnih kapaka i periorbitalne zone bili su umereni kod svih bolesnika (100%). Ostale komplikacije nisu postojale, osim unilateralne epistakse kod jednog (0,66%) bolesnika, desetog postoperativnog dana. Najveći broj operisanih (52,97%) je odmah posle operacije mogao normalno da diše

kroz nos. Bolesnici su opšti komfor nakon operacije uglavnom opisivali najvećom ocenom (74,17%). Većina bolesnika bila je zadovoljna estetskim rezultatom posle sedam dana (58,28%) kao i posle mesec dana (52,32%). Bilo je veoma zadovoljnih bolesnika, sedmog dana - 27,15% i tridesetog dana - 39,73%. **Zaključak.** Smatramo da je rinoplastika bez tamponade i imobilizacije bezbedna, ugodna i ekonomična. Intenzitet bola, otoka i ekhimoza je nizak, kao i učestalost drugih komplikacija.

#### Ključne reči:

**rinoplastika; hirurgija, operativne procedure; postoperativni period; postoperativne komplikacije; bolesnik, zadovoljstvo.**

### Introduction

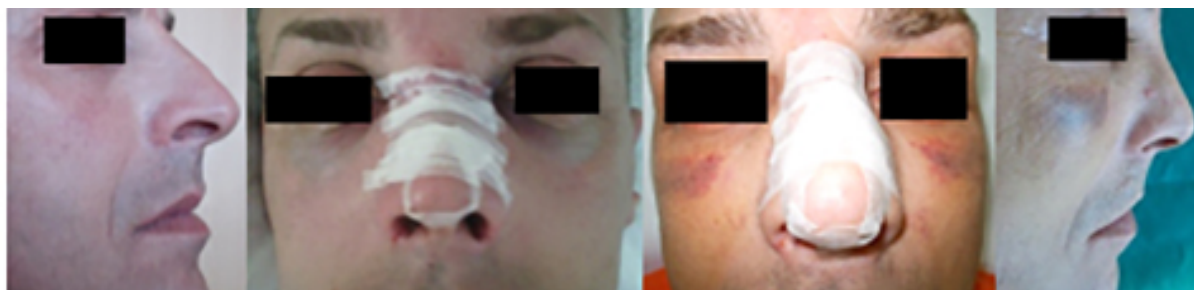
Rhinoplasty is one of the most common aesthetic surgeries. The most surgeons use nasal packing and external immobilization with splint because of hemostasis and fixation of the operated cartilages and bones<sup>1-5</sup>. In addition, nasal packing is used to prevent mucosal adhesions, and for that purpose, different materials are used, usually paraffin gauze<sup>3-12</sup>. For external fixation, plaster of Paris is most commonly used<sup>3-23</sup>. There are many complications in corrective rhinoplasty that may occur<sup>1,2,4</sup>. The postoperative period is accompanied by edema of the nose and glabella, with hematoma in the periorbital region, which are considered as less important, but represent common complications. After nasal tamponade, a patient breathes through the mouth, which is followed by drying of the upper respiratory tract and sometimes by a stimulatory cough. The patients describe the presence of nasal packing, especially its removal, as unpleasant and sometimes painful. There are cases of tamponade migration toward the pharynx causing palate irritation and vomiting as well as allergic or toxic complications. In addition, in a case of a postoperative infection, diagnosis is difficult. During external immobilization, skin lesion of the nose may occur due to compression which is noticed in practice only after the removal of the splint.

brought in connection with these proceedings, we set a goal to perform corrective rhinoplasty without nasal packings and external immobilization with rigid materials and to analyze the results of these types of operations.

### Methods

Prospective clinical study of the consecutive cases series was conducted at the Center for Plastic Surgery, Clinical Center "Kragujevac" in Kragujevac, in the period from 1997 to May 2016, after rhinoplasty without nasal packings and immobilization of the nose with rigid materials, but only with skin adhesive tapes.

All the surgeries were done by the same surgeon and under general endotracheal anesthesia. The closed method of rhinoplasty was used with intercartilagineous, transcollumelar and piriform incisions. Reduction of the lateral cartilage, caudal and dorsal edge of the septum, bone and cartilage resection of the "hump" were done as well as lateral osteotomy and resection of the lateral crus of alar cartilages. At the end of the surgery, all endonasal incisions were sutured with fast absorbable sutures 4-0 with a cutting needle 3/8, and sterile adhesive skin tapes were placed on the nose (Figure 1). None of the patients had a nasal tamponade or an external immobilization. Antibiotic therapy was not applied neither preoperatively, nor postoperatively. In the



**Fig. 1 – a) before surgery; b) 24h after surgery; c) day 3 after surgery; d) day 7 after surgery.**

Assuming that tamponade of the nose and external immobilization in corrective rhinoplasty are not necessary and that some of the complications of this surgery can be

postoperative period, head and chest were elevated to 30°, hygiene and disinfection of the anterior part of the nasal tunnels were carried out and oral analgesics were prescribed

only in the case of the pain. The patients were dismissed from the hospital after 24 h. Check-ups were performed on postoperative days 3 and 7 when the adhesive tapes were removed. After that, check-ups were performed after 1 month, 3 months and 1 year. All patients were photographed before and after surgery (after 24 h and on the day 7).

The exclusion criteria in the study were: minors, patients with diseases or scarred skin of the nose, persons who previously had this surgery, people with severe forms of systemic diseases and psychiatric patients. Also, the exclusion criteria were cosmetic surgery patients who had unrealistic requests, for example, thinking that the surgery would make him/her become another person or would solve all their problems, patients who wanted their nose look like some other person's nose, patients who wanted to undergo surgery because their family members pushed them to do so or patients who did not know what they exactly wanted.

In assessing the outcome, 6 following methods were used: analysis of the occurrence and type of postoperative

complications; analysis of the pain intensity; a degree of eyelid edema and ecchymosis 24 h after the surgery; a degree of restriction of nasal respiration; the overall comfort of the patient after the surgery and patient satisfaction with the aesthetic result, on the day 7 after the surgery and after removing the skin strips and after 1 month.

In assessing postoperative pain, after 24 h, the visual analogue scale (VAS) was used, in a range from 1 to 10: no pain, mild pain, moderate pain, severe pain and the worst pain possible. Patients were asked "Do you have any pain?". If the answer was "Yes", patients were asked to record the pain level in the scale chart (Figure 2).

Palpebral swelling and ecchymosis, 24 h after the surgery, was recorded by the surgeon using a Surgeon Periorbital Rating of Edema and Ecchymosis (SPREE) scale, from 0 to 5 (Table 1, Figure 3).

The degree of restriction of nasal respiration was investigated by using the questionnaire with 4 possible answers: easy breathing through both nostrils, breathing

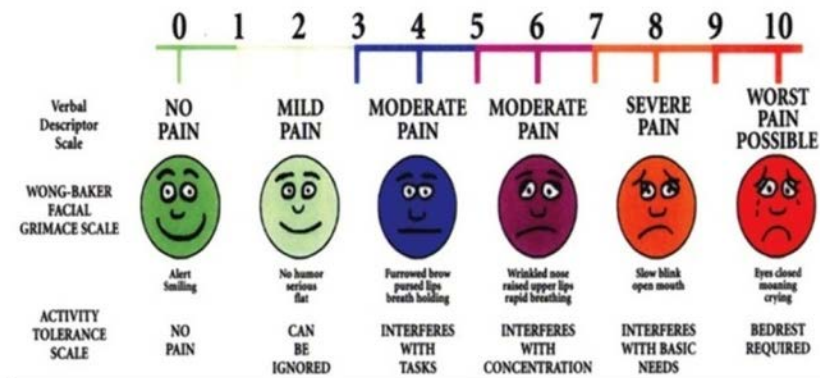


Fig. 2 – Pain assement by visual analog scales.

Table 1

**Surgeon Periorbital Rating of Edema and Ecchymosis (SPREE) questionnaire within 24 h**

Score	Description
0	No ecchymosis. No edema.
1	Up to medial one third of the lower and/or upper eyelid. No coverage of iris with eyelids.
2	Medial half of the upper and/or lower eyelid. Slight coverage of iris with swollen eyelids.
3	Up to the full length of the lower and/or upper eyelid. Full coverage of iris with swollen eyelids.
4	Entire part of the lower and upper eyelid and/or conjunctiva. Full coverage of eyes.
5	Extension of ecchymosis below the malar bone.

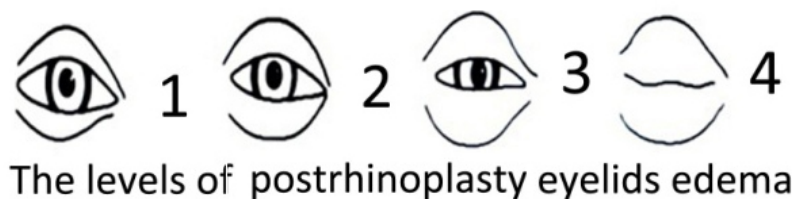


Fig. 3 – Degrees 1–4 in Surgeon Periorbital Rating of Edema and Ecchymosis (SPREE).

through one nostril, difficult breathing through both nostrils, inability to breathe through the nose.

The overall comfort of the patient after surgery was examined so that the patients answered using these three options: good, no opinion, bad.

The satisfaction with the aesthetic result was assessed by the surgeon, after verbal communication with patients, on the day 7 after surgery, when the adhesive sterile skin tapes were removed, and after 1 month. The patient satisfaction was analyzed using 1 to 5 scale: very satisfied, satisfied, without opinion, dissatisfied and very dissatisfied (Table 2).

The results were analyzed by descriptive statistics, showing the percentage of certain categorical variables.

## Results

The total of 151 rhynoplasties without nasal packing and without splinting were done. All the patients were Caucasians. The age ranged from 18 to 47 years and majority of patients were young (on average 23.18%). Females were significantly more prevalent (72.18%).

There were no complications in the immediate postoperative period of 24 h after surgery. In one (0.66%) female patient, unilateral epistaxis occurred at the 10th postoperative day and was resolved by a one-day tamponade (Figure 4).

The majority of patients (54.97%) had easy breathing through both nostrils, immediately after surgery. Thirty-three (23.84%) patients could easily breathe through one nostril and in 20 (13.25%) patients difficult breathing through the both nostrils was present. The smallest group consisted of 12(7.95%) patients, with inability of breathing through nose.

The general impression about the overall comfort after the surgery was mainly good in the majority (74.17%) of patients. Thirty-four (22.52%) patients had no opinion about postoperative comfort and 5 (3.31%) patient found it bad.

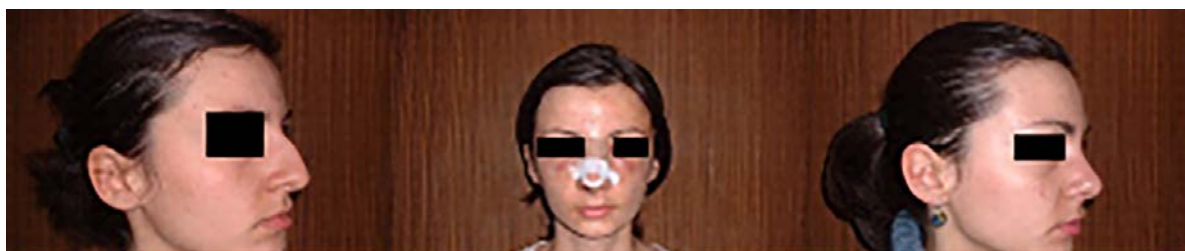
On the seventh day after rhinoplasty, when sterile skin adhesive tapes were removed, the majority (58.28%) of patients were pleased with the aesthetic result. Among them, 41 (27.15%) very were satisfied. The rest (14.57%) of the patients had no clearly defined opinions. There were no dissatisfied and very dissatisfied patients. After 1 month, the results were different (Table 2). There were 19 (12.6%) more very satisfied patients, 9 (5.96%) less satisfied ones and much less (12.58%) patients without opinion. Unlike the 7th postoperative day, 8 (5.29%) patients were dissatisfied and 1 patient was very dissatisfied.

## Discussion

The goal of any surgery, especially aesthetic surgery, is to achieve maximum result, without complications and with

**Table 2**  
**The patients satisfaction after 7th day and one month after surgery**

Degree of satisfaction	Number of patients	
	7th day	One month
Very satisfied	41	60
Satisfied	88	79
Without opinion	22	3
Dissatisfied	0	8
Very dissatisfied	0	1



**Fig. 4 – Left: patient before surgery; In the middle: 3rd postoperative day; Right: 7th postoperative day after tapes removal.**

Analysis of the pain intensity, showed that most (40.39%) patients had mild pain and 39.07% of the patients had no pain at all. The smallest group (20.54%) had moderate pain. No patient had severe, nor the worst pain possible.

The extent of eyelid edema and periorbital ecchymosis, measured at the scale 0–5, was in all patients (100%) in the category 1: up to medial one-third of the lower and/or upper eyelid; no coverage of iris with eyelids.

high comfort of the operated patient. Many patients, when they come for the first time to the surgeon with a desire to do rhinoplasty, are already informed about the unpleasant postoperative period, because of the tamponade, external immobilization, swelling, hematoma and pain. Some of these patients frequently asked questions related to the time of the tamponade removal. According to literature data, there are different opinions about it, and this period rates from 1 to 10 days<sup>24</sup>.

The fact that the tamponade of the nose and external fixation in rhinoplasty are performed by using different materials, it can be concluded that there is no ideal method. For tamponade, the paraffine gauze is used, the gauze with antibiotic ointment or tampons made from other materials such as polypropylene<sup>8</sup>, polyethylene oxide gel<sup>9, 10</sup>, respiratory tubes, vaginal tampons<sup>11</sup>, X-ray film<sup>13</sup> and others. For external fixation, nasal splints that are most commonly used are plaster of Paris, metal and various plastics<sup>16-23</sup>.

There are many possible complications of rhinoplasty<sup>1, 2, 4, 25-38</sup>. Some of them are in fact inevitable, such as swelling of the nose and bruises in the periorbital region, and sometimes subconjunctival ecchymosis. Other complications include bleeding, dislocation of the bone and cartilage structures, mucosal synechia and perforation of the nasal septum. As a result of the nasal tamponade, postoperative nasal obstruction may occur due to nasal valve collapse with inspirium or allergic rhinitis with chronic nasal mucosal edema. There are other rare complications, such as necrosis of the skin of the nose and eyelids, subcutaneous emphysema with possible propagation to the mediastinum, blindness due to central retinal artery occlusion, lesions of the lacrimal system, neuromas, numbness on the nose, hiposmia, rhinoliqorrhoea, endocranial and some other complications like cardiac arrest due naso-cardiac reflex or discoloration of incisors. The second group of complications include those of aesthetic character and they are often a result of the disproportion of the cartilage-bone structure.

An extreme early complication of rhinoplasty is usually bleeding within the first 24 h of surgery. This is one of the reasons why most surgeons use tamponade and firm external fixation of the nose. In order to prevent dislocation of the operated structures, besides tamponade, most surgeons use splinting at the end of the surgery. In practice, we have noticed that this immobilization after a few days becomes inadequate, because of the resolution of edema, and that immobilization loses its meaning. There are described cases of skin roughness or erosion after the splint removal due to compression. Moreover, there are cases of conjunctival irritation with gypsum particles. According to relevant literature, there are numerous complications of endonasal tamponade<sup>22-30</sup>. Besides being uncomfortable for a patient, nose tamponade may cause difficulty in breathing, odor and pain. There may also occur hypoxia, obstructive apnea, prolonged rhinorrhoea, pressure changes in the middle w reduced drainage in the case of the wounds infection. There are findings that suggest foreign body reaction, formation of mucous cyst, allergic complications and paraffin cyst when paraffin tamponade is used and endonasal incisions are not completely sutured. An allergic complications are possible as well as toxic shock syndrome (TSS). Toxic shock syndrome is an acute, drastic, multisystem disease that can occur in various pathological conditions. It has been described after corrective rhinoplasty too, mainly when the nose was tamponaded<sup>33-36</sup>. TSS is usually manifested by hypotension, nausea, vomiting, diarrhea and erythrodermia.

After tamponade of the nose, migration is possible towards the pharynx because of the inspirium reflex, vomiting may also occur as well as aspiration or ingestion of tampons and even bowel perforation<sup>29-38</sup>. Sometimes, we can see in practice, that some patients try to take out the tamponade in the postoperative period. According to some studies<sup>39-44</sup>, there were significantly more postoperative pain, headache, epiphora, dysphagia, and disturbed sleep at night after surgery in patients whose nose was tamponaded. After a few days, due to potentiated rhinorrhoea, nasal tamponades and poor hygiene, an unpleasant odor started to appear. In addition, the length of the tamponade itself is inconsistent, and is rather based on an individual assesment of the surgeon<sup>24</sup>.

The removal of a nasal packing is uncomfortable and mostly painful. There are recommendations to use some kind of anesthesia during the removal of the tamponade<sup>25-27</sup>. Besides, the nose tamponade is often the reason for preventive use of antibiotics, which sometimes results in longer hospitalization.

Stucker and Ansel<sup>38</sup> were the first to suggest that nasal packing should not routinely be used because of possible complications. Guyuron<sup>39</sup> has released the results of a study on patients who underwent septorhinoplasty and concluded that complication rate was lower in those with the nose tamponade. Several studies were done later with suggestion that the nose tamponade did not give an effect<sup>40-44</sup>. Camirand<sup>41</sup> and Camirand et al.<sup>42</sup>, concluded that it was not necessary to do even external nasal immobilization and that the septoplasty could be done in the same way.

In our study, epistaxis did not occur immediately after the surgery in any of the patients.

Splint is used to immobilize the bone and septum and to decrease the pain and swelling. Our results are the same as the results of Camirand<sup>41</sup> and Camirand et al.<sup>42</sup>, because there were no bone and septal displacements or excessive pain and swelling. The placement of adhesive sterile skin tapes was quite enough for adequate nose fixation, because the nose does not have joints. Good example in support of this opinion is a fact that even when a fracture without dislocation of the bone that has the joints, such as the phalanx of a hand, fixation with the tape to the adjacent finger is quite sufficient. Nasal packing is used to maintain immobilization and hemostasis, to prevent bleeding, septal hematoma and necrosis as well as to prevent synechia between the septum and lateral nasal wall. Our results differ from those of Guyuron<sup>39</sup>, but they are the same as results of many other researchers<sup>41-51</sup> because postoperative bleeding occurred in only 1 patient on the day 10 after surgery, when the most surgeons already removed internal packing. Also, there were no cases of the bone and septal displacements, septal hematoma, septal necrosis and synechia. We found that this technique of rhinoplasty reduced pain, extent of eyelid edema and periorbital ecchymosis and discomfort of the patients. This is in correlation with the results of many other authors<sup>38, 41-51</sup>. We suggest that corticosteroid therapy and the use of lidocaine in prevention of the edema and ecchymosis in rhinoplasty<sup>46, 48, 52</sup> are not necessary, when using this technique of rhinoplasty.

We believe that the prevention of bleeding after rhinoplasty, apart from general surgical principles such as meticu-

lous surgical technique, osteotomy with as less trauma as possible, is very important, by using the small diameter osteotomes, but large enough for the purpose of surgery. In the same meaning, digital compression, for a few minutes immediately after the osteotomy, may be very useful. We believe that it is important that all of the endonasal incisions should be sutured at the end of surgery. We also believe that it is important that during the surgery and on waking up from anesthesia, the patient has controlled blood pressure and elevated head. Of course, preoperative selection of the patients is very important, as it is for any cosmetic surgery, especially in the context of understanding the possible complications and importance of cooperation, in order to prevent certain complications.

## Conclusion

On the basis of our results, we can conclude that the nose tamponade and external immobilization are not necessary in corrective rhinoplasty. Comfort of surgery is higher, and because the patient can breathe through the nose, oxygenation is better. There is less pain, swelling and ecchymosis of the nose and the surrounding regions. Also, incidence of complications is lower. The method we have described is considerably more economical because the operative time is shorter, the usage of medical supplies is lesser, there is no need for antibiotics and other preventive therapy and period of hospitalization is shorter.

## R E F E R E N C E S

1. *Christophel JJ, Park SS.* Complications in rhinoplasty. *Facial Plast Surg Clin North Am* 2009; 17(1): 145 – 56, vii.
2. *Holt GR, Garner ET, McLarey D.* Postoperative sequelae and complications of rhinoplasty. *Otolaryngol Clin North Am* 1987; 20(4): 853 – 76.
3. *Donald PJ.* Postoperative care of the rhinoplasty patient. *Otolaryngol Clin North Am* 1975; 8(3): 797–806.
4. *Cochran CS, Landecker A.* Prevention and management of rhinoplasty complications. *Plast Recon Surg* 2008; 122(2): 60–7.
5. *Cochran CS, Ducic Y, DeFatta RJ.* Current concepts in the postoperative care of the rhinoplasty patient. *South Med J* 2008; 101(9): 935–9.
6. *Kamer FM, Parkes ML.* An absorbent, non-adherent nasal pack. *Laryngoscope* 1975; 85(2): 384 – 8.
7. *Fernbach JC.* Nasal packing after surgery. *JAMA* 1982; 248(19): 2452.
8. *Bernal-Sprekelsen M.* The postoperative nasal dressing. A new intranasal splint. *Rhinology* 1990; 28(3): 197 – 203.
9. *Salassa JR, Pearson BW.* Polyethylene oxide gel. A new intranasal dressing after septorhinoplasty. *Arch Otolaryngol Head Neck Surg* 1991; 117(12): 1365 – 7.
10. *Egelund E, Jeppesen F.* Respiratory tubes with nasal packings following septorhinoplasty. *Rhinology* 1992; 30(3): 193 – 204.
11. *Lusthaus SN, Benmeir P, Newman A, Weinberg A, Talisman R, Wexler MR.* Nasal tampon packing in rhinoplasty: A simple and safe method of hemostasis. *Ann Plast Surg* 1992; 29(5): 469 – 70.
12. *Weber R, Hochapfel F, Draf W.* Packing and stents in endonasal surgery. *Rhinology* 2000; 38(2): 49 – 62.
13. *Gryskiewicz JM.* Intranasal splint obtained from X-ray film. *Plast Reconstr Surg* 2001; 108(7): 2161.
14. *Kim MG, Baek RM, Minn KW, Heo CY, Kwon SS, Park CY.* Nasal packs with X-ray indicators. *Ann Plast Surg* 2006; 56(3): 342 – 3.
15. *Sarıgüney Y, Demir Y, Kandal S, Özmen S, Latıföglü O.* Vertically split merocel tampon has advantages in nasal packing. *Plast Reconstr Surg* 2006; 117(5): 1646 – 7.
16. *Rettinger G, Masing H.* Nasal splinting with thermoplastic material. *HNO* 1980; 28(9): 320. (German)
17. *Kalisman M.* An easy method of nasal splinting. *Plast Reconstr Surg* 1981; 68(5): 793.
18. *Webster RC, Smith RC, Smith KF, Barrera A, Hamdan US.* External splinting of the nose. *Laryngoscope* 1983; 93(12): 1615 – 6.
19. *Mabler D.* Securing of the nasal skin under the cast in rhinoplasty. *Aesthetic Plast Surg* 1986; 10(4): 235 – 6.
20. *Seitchik MW.* A "safe", nasal splint lined with dental impression compound. *Plast Reconstr Surg* 1986; 77(1): 164.
21. *Matti BA, Nicolle FV.* Use of Orthoplast as nasal splint. *Br J Plast Surg* 1986; 39(3): 414 – 6.
22. *Reynaud JP, Baron JL, Penin M, Chadoint F.* Heat-moulded plastic splint for the nose. *Ann Chir Plast Esthet* 1990; 35(6): 496 – 7. (French)
23. *Abn MS, Maas CS, Monbian N.* A novel, conformable, rapidly setting nasal splint material: Results of a prospective study. *Arch Facial Plast Surg* 2003; 5(2): 189 – 92.
24. *Lubianca-Neto JF, Sant'anna GD, Mauri M, Arrarte JL, Brinckmann CA.* Evaluation of time of nasal packing after nasal surgery: A randomized trial. *Otolaryngol Head Neck Surg* 2000; 122(6): 899 – 901.
25. *Lachanas VA, Karatzias GT, Pinakas VG, Hatzioannou JK, Sandris VG.* The use of tetracaine 0. 25% solution in nasal packing removal. *Am J Rhinol* 2006; 20(5): 483 – 4.
26. *Karasiyan K, Yılmaz F, Gulu N, Yigit B, Kocoglu H.* The effect of prilocaine and prilocaine plus meperidine infiltration on the pain during nasal packing removal. *Rhinology* 2007; 45(4): 321 – 4.
27. *Yılmazçer C, Sener M, Yılmaz I, Erkan AN, Cagici CA, Donmez A, et al.* Pre-emptive analgesia for removal of nasal packing: A double-blind placebo controlled study. *Auris Nasus Larynx* 2007; 34(4): 471 – 5.
28. *Georgiou I, Farber N, Mendes D, Winkler E.* The role of antibiotics in rhinoplasty and septoplasty: A literature review. *Rhinology* 2008; 46(4): 267 – 70.
29. *Becker H.* Paraffinoma as a complication of nasal packing. *Plast Reconstr Surg* 1983; 72(5): 735 – 6.
30. *Montgomery PQ, Khan JI, Feakins R, Nield DV.* Paraffinoma revisited: A post-operative condition following rhinoplasty nasal packing. *J Laryngol Otol* 1996; 110(8): 785 – 6.
31. *Liu ES, Kridel RW.* Post-rhinoplasty nasal cysts and the use of petroleum-based ointments and nasal packing. *Plast Reconstr Surg* 2003; 112(1): 282 – 7.
32. *Bracaglia R, Fortunato R, Gentileschi S.* Endoscopic excision for post-rhinoplasty mucous cyst of the nose. *Br J Plast Surg* 2005; 58(2): 271 – 4.
33. *Toback J, Fayerman JW.* Toxic shock syndrome following septorhinoplasty. Implications for the head and neck surgeon. *Arch Otolaryngol* 1983; 109(9): 627 – 9.
34. *Barbour SD, Shlaes DM, Guertin SR.* Toxic-shock syndrome associated with nasal packing: Analogy to tampon-associated illness. *Pediatrics* 1984; 73(2): 163 – 5.
35. *Jacobson JA, Kasworm EM.* Toxic shock syndrome after nasal surgery. Case reports and analysis of risk factors. *Arch Otolaryngol Head Neck Surg* 1986; 112(3): 329 – 32.
36. *Wagner R, Toback JM.* Toxic shock syndrome following septoplasty using plastic septal splints. *Laryngoscope* 1986; 96(6): 609 – 10.
37. *Yanagisawa E, Latorre R.* Choking spells following septorhinoplasty secondary to displaced nasal packing. *Ear Nose Throat J* 1995; 74(11): 744 – 6.

38. *Stucker FJ, Ansel DG.* A case against nasal packing. *Laryngoscope* 1978; 88(8 Pt 1): 1314 – 7.
39. *Guyuron B.* Is packing after septorhinoplasty necessary? A randomized study. *Plast Reconstr Surg* 1989; 84(1): 41 – 4; discussion 45 – 6.
40. *Reiter D, Alford E, Jabourian Z.* Alternatives to packing in septorhinoplasty. *Arch Otolaryngol Head Neck Surg* 1989; 115(10): 1203 – 5.
41. *Camirand A.* Nasal packing in rhinoplasty and septorhinoplasty: It is wiser to avoid. *Plast Reconstr Surg* 1999; 104(4): 1198.
42. *Camirand A, Doucet J, Harris J.* Nose surgery (rhinoplasty) without external immobilization and without internal packing: A review of 812 cases. *Aesthetic Plast Surg* 1998; 22(4): 245 – 52.
43. *Lemmens W, Lemkens P.* Septal suturing following nasal septoplasty, a valid alternative for nasal packing?. *Acta Otorhinolaryngol Belg* 2001; 55(3): 215 – 21.
44. *Al-Arfai AA, Al-Smiabbi JN, Al-Harthy S, Al-Essa M.* Nasal packing in cosmetic and functional nasal surgery. *Saudi Med J* 2008; 29(7): 994 – 7.
45. *Erisir F, Oktem F, Inci E.* Effect of steroids on edema and ecchymosis in rhinoplasty. *Turck Arch ORL* 2001; 39(3): 171 – 5.
46. *Koc S, Gürbüzler L, Yaman H, Eyibilen A, Süren M, Kaya Z, et al.* The effectiveness of steroids for edema, ecchymosis, and intraoperative bleeding in rhinoplasty. *Am J Rhinol Allergy* 2011; 25(2): e95 – 8.
47. *Kelley BP, Koshy J, Hatef D, Hollier LH Jr, Stal S.* Packing and postoperative rhinoplasty management: A survey report. *Aesthet Surg J* 2011; 31(2): 184 – 9.
48. *Gun R, Yorgancılar E, Yıldırım M, Bakır S, Topcu I, Akkus Z.* Effects of lidocaine and adrenaline combination on postoperative edema and ecchymosis in rhinoplasty. *Int J Oral Maxillofac Surg* 2011; 40(7): 722 – 9.
49. *Zayyan E, Bajin MD, Aytemir K, Yılmaz T.* The effects on cardiac functions and arterial blood gases of totally occluding nasal packs and nasal packs with airway. *Laryngoscope* 2010; 120(11): 2325 – 30.
50. *Günaydin RÖ, Aygenc E, Karakullukcu S, Fidan F, Celikkanat S.* Nasal packing and transseptal suturing techniques: Surgical and anaesthetic perspectives. *Eur Arch Otorhinolaryngol* 2011; 268(8): 1151 – 6.
51. *Cukurova I, Cetinkaya EA, Mercan GC, Demirhan E, Gumussoy M.* Retrospective analysis of 697 septoplasty surgery cases: Packing versus trans-septal suturing method. *Acta Otorhinolaryngol Ital* 2012; 32(2): 111 – 4.
52. *Sakallioğlu Ö, Polat C, Soylu E, Düzzer S, Orhan İ, Akyığıt A.* The efficacy of tranexamic acid and corticosteroid on edema and ecchymosis in septorhinoplasty. *Ann Plast Surg* 2015; 74(4): 392 – 6.

Received on July 1, 2016.

Revised on July 25, 2016.

Accepted on July 25, 2016.

Online First September, 2016.